

Beware falling rocks on the biliary-pancreatic route!

ESIM 2011

Dr. Madalina Buzoiu

Coltea Clinical Hospital

Bucharest



F.G., male, 55 years old


- sent with high suspicion of pancreatic body cancer and liver metastasis(CT)
- recurrent abdominal pain and nausea

- The patient history- 3 bouts of pancreatitis in 2008, July and Sept 2010, erosive gastritis and oesophagitis (EGDS- Sept 2008)
- No current medication
- Tabagism
- Alcoholism

Physical exam

- HR=80/min, BP=130/75 mmHg, RR=16/min, BMI=25kg/m²
- no weight loss
- normal body temperature, no jaundice
- no palpable lymph nodes
- normal breath sounds, normal heart sounds, no heart murmurs
- normal shaped abdomen, free herniary points, no peritoneum irritation signs, pain to deep palpation of the RUQ of the abdomen
- rounded contour of the liver edge, elastic consistency, regular hepatic surface, hepatic arrow 12 cm long
- no splenomegaly, no abdominal signs of portal hypertension
- normal stools, normal urines
- no palpable kidneys
- normal neurological exam

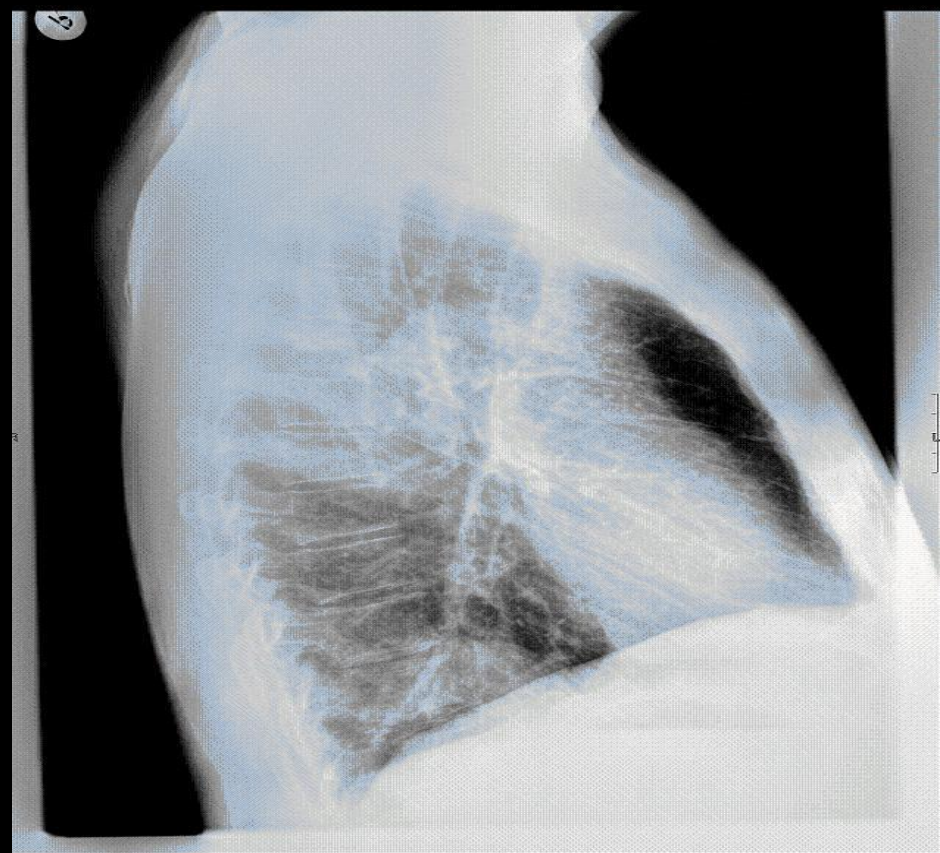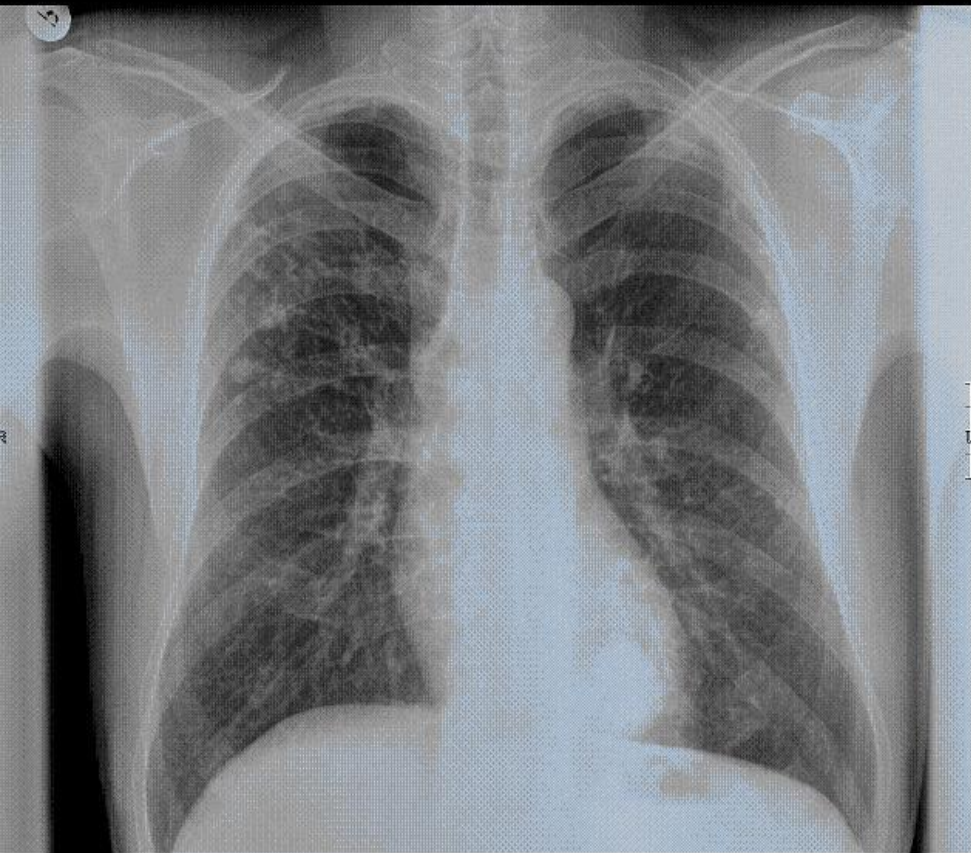
Poor physical findings, alcoholism, recurrent abdominal pain

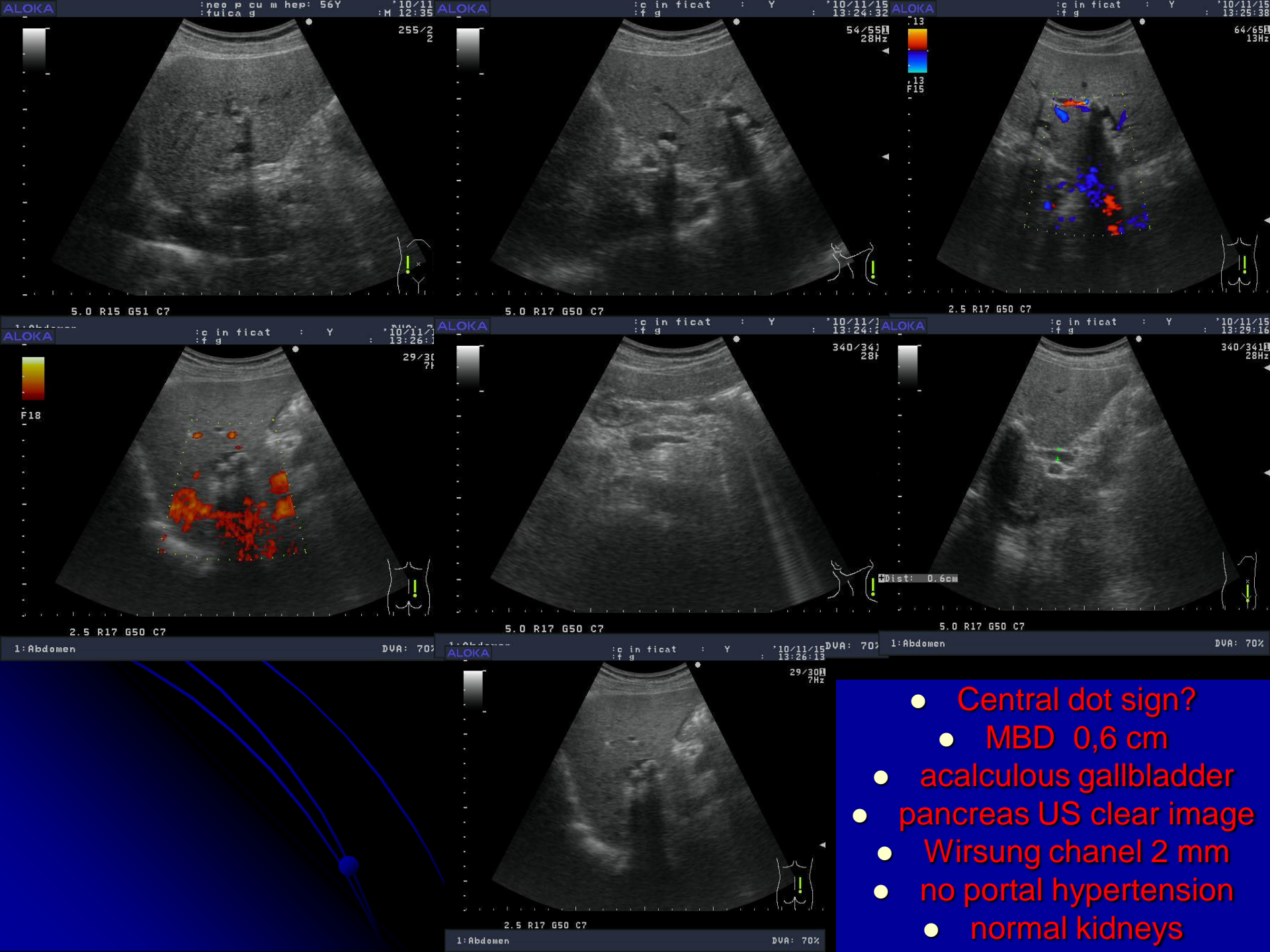
- Pancreatic cancer?
 - Biliary lithiasis?
 - Pancreatitis?
 - Ethanollic hepatitis?
- 

Lab results

patient	14.07.2010	16.08.2010	10.11.2010	normal ranges
WBC			7.3 *10 ⁹ /μL	4-9.0X10 ⁹ /μL
HGB	13,5g/dl	13.2g/dl	16.3 g/dl	11.0-16,5 g/dl
MCV	106	107	101 fL	82-96 fL
ESR			15 mm/1ora	2-14 mm/1ora
Fibrinogen			469 mg/dl	200-450 mg/dl
INR			0.87 INR	0,89-1,08 INR
GLI			96 mg/dl	65-105 mg/dl
CREA			0.8 mg/dl	0,9 mg/dl
URIC			7.1 mg/dl	2,5-6,2 mg/dl
AST	37U/l		32 U/L	14-36 U/L
ALT	61U/l		34 U/L	9-52 U/L
GGT	274U/l	81U/l		30-70 U/l
LDH			413 U/L	313-618 U/L
TBIL			0.8 mg/dl	02-1,3 mg/dl
DBIL				
BU				
PALK			71 U/L	50-115 U/L
PROT			6.8 g/dl	6-8 g/dl
ALB				
AMYL	136U/l	75U/L	47 U/L	70-90U/L
LIPA			141 U/L	<170 U/L
CHOL			207 mg/dL	130-239 mg/dL
TRIG			103 mg/dl	70-175 mg/dl
AFP			6.10 iu/mL	<6iu/mL
CEA		5.62 ng/ml	6.73 ng/mL	<10ng/mL
CA19-9		48.74 U/ml	24.1 u/mL	<40u/mL
Ca seric			9.4 mg/dl	9-10mg/dl

Chest X-Ray





- Central dot sign?
- MBD 0,6 cm
- acalculous gallbladder
- pancreas US clear image
- Wirsung chanel 2 mm
- no portal hypertension
- normal kidneys

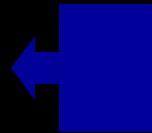
DD≠

recurrent abdominal pain

recurrent pancreatitis

obstructive jaundice

colangitis



➤ **biliary cysts** –Todani clsf

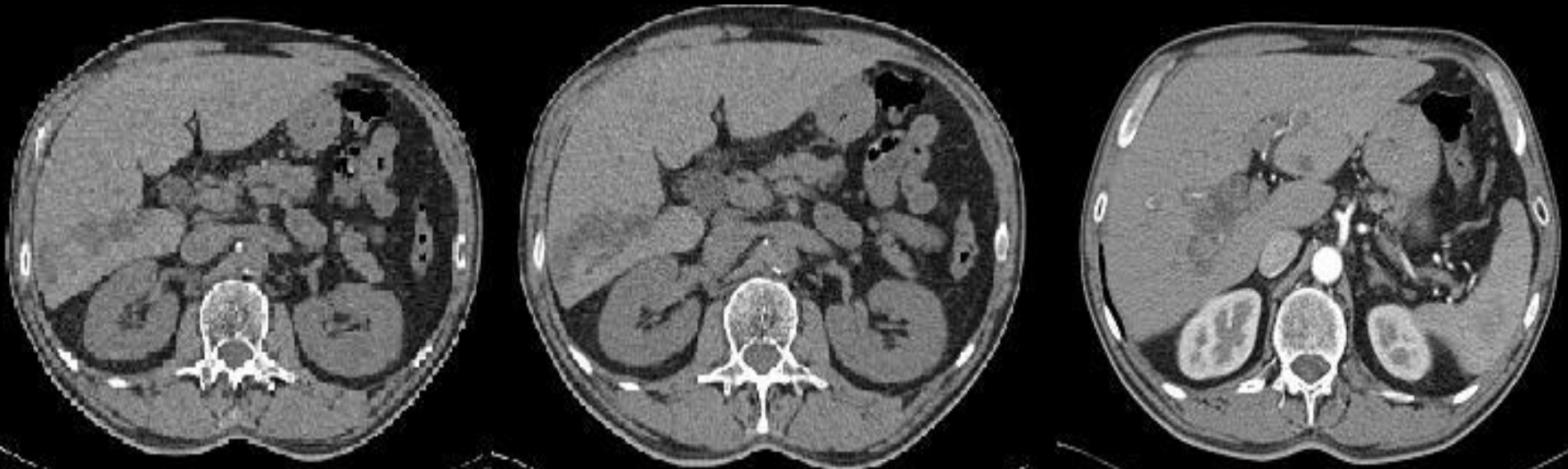
1. choledochal cysts
2. diverticulum cysts of EHBD
3. choledochocele cysts
4. multiple cysts- IHBD and EHBD
5. IHBD cysts ???

➤ **biliary hamartomas**

➤ **policystic liver disease**

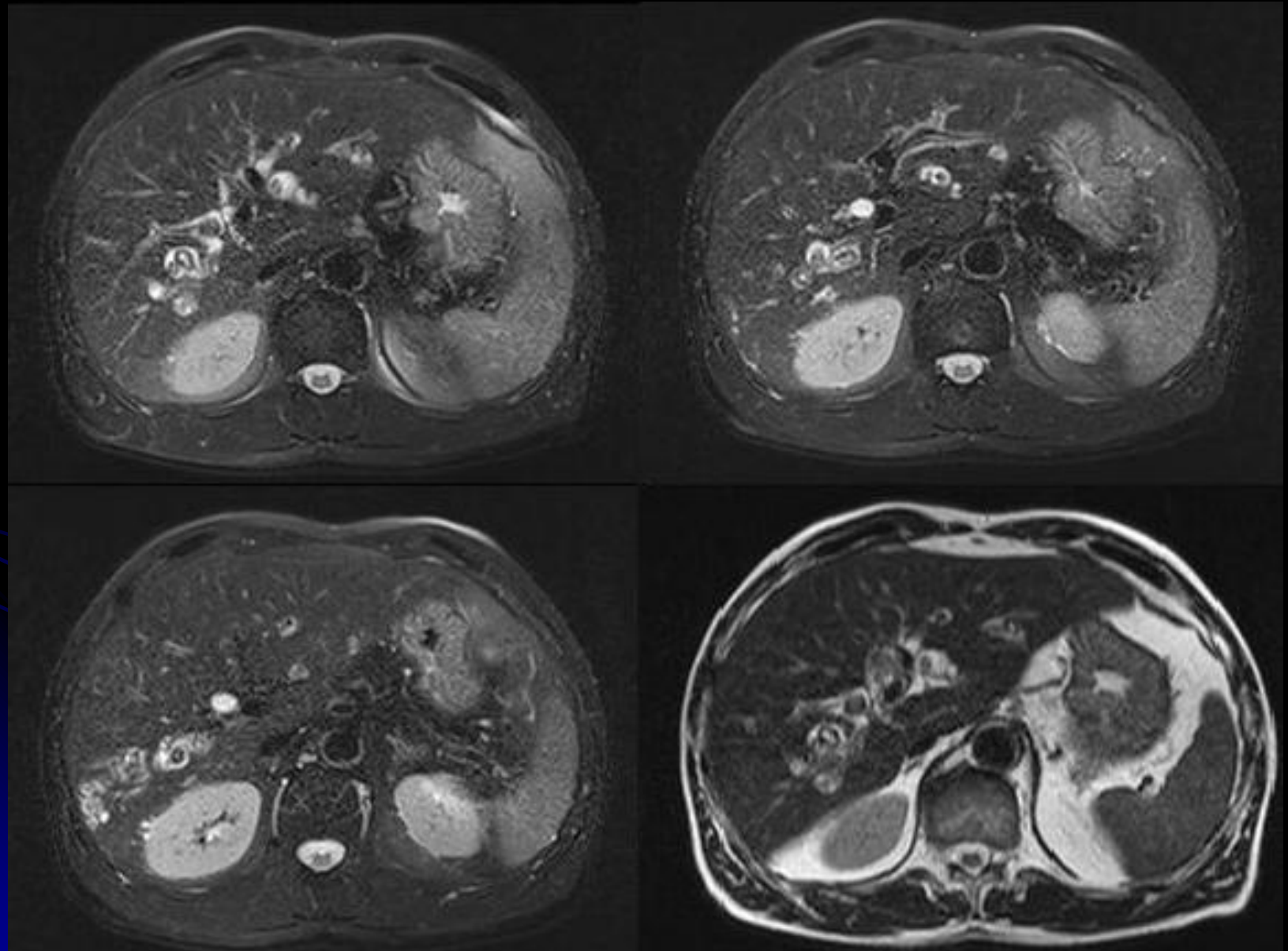
➤ **multiple liver abscesses.**

Abdominal CT nov2010



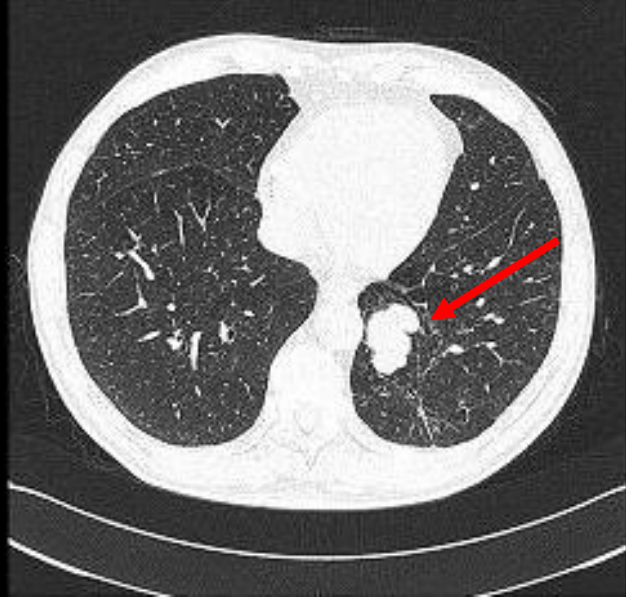
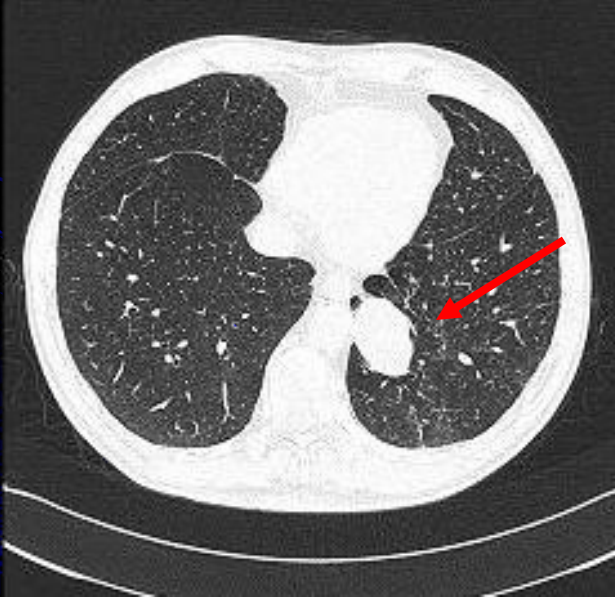
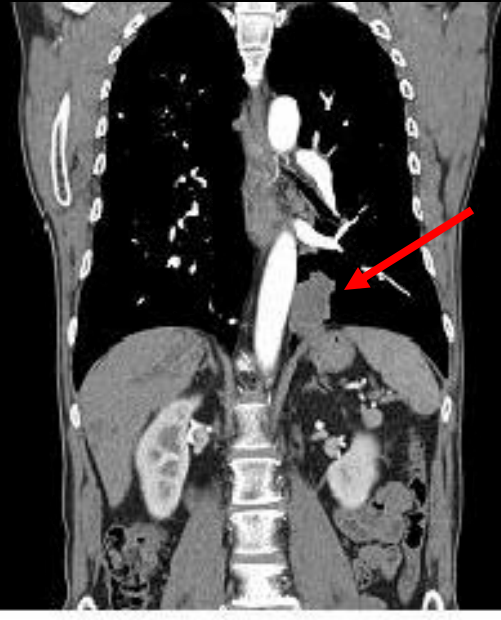
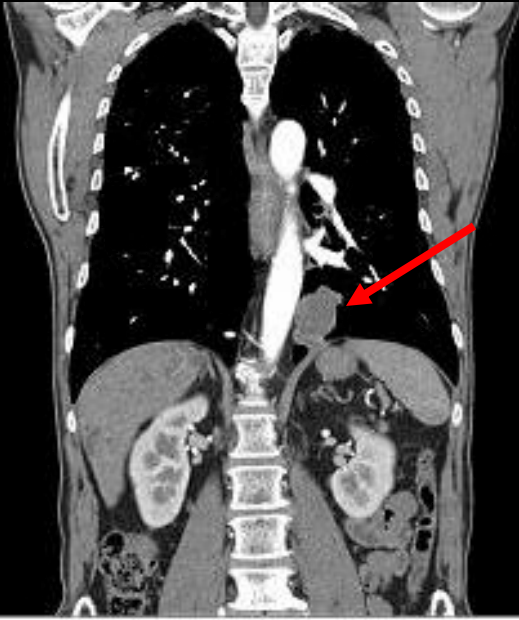
- cystic dilation of the IHBD with microlithiasis
- MBD dilation, normal choledochal aspect within the intrapancreatic course,
- Wirsung channel clearly visible; no pancreatic mass

**ERCP, PTC-risk+++
MRC-Se+++**



Caroli disease

- intrahepatic bile duct cysts -the simple type -60-70% coexisting with MSK
- Caroli syndrome-the periportal fibrosis type –ARPKD
- Progression:cirrhosis, portal hypertension, recurrent cholangitis,sepsis,lithiasis
- No lung pathology associated reported, yet our patient?



NO SIGNIFICANT
ADENOPATHY
NO METASTASIS
NO Lymphadenopathy
NO
NO

NO SIGNIFICANT
ADENOPATHY
NO METASTASIS
NO Lymphadenopathy
NO
NO

NO
NO
NO

NO
NO
NO

NO
NO
NO

NO
NO
NO

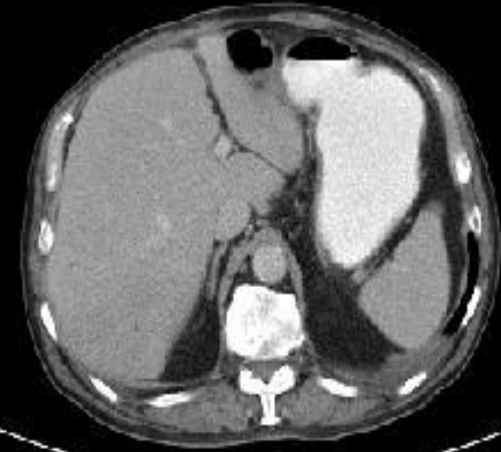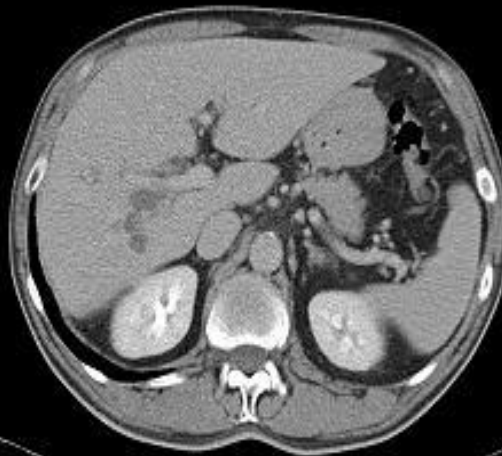
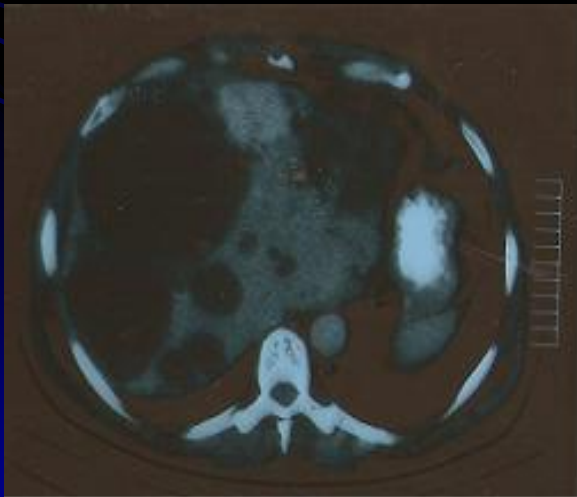
NO
NO
NO

NO
NO
NO



Final diagnosis

- *Caroli disease with multiple IHBD lithiasis and choledochal lithiasis*
- *Recurrent pancreatitis*
- *Pulmonary cyst*
- *Case series: PCLD x1 Caroli x3 L abscesses x2*



Take away message

- Biliary cysts should be included in the differential diagnosis of recurrent abdominal pain, pancreatitis, obstructive jaundice, or cholangitis
- Most patients do not present with the classic triad of pain, jaundice and abdominal mass
- Biochemical tests only reflect the degree of biliary obstruction and infection
- Correct diagnosis depends on the use of imaging studies.

CT July 2010

- Pancreatic body mass hypointense pre and post contrast
- Acute pancreatitis?
- Do not missinterpretate hypointense hepatic lesions!(T2)

Se: 3/6
Im: 23/62
Ac: 11:10.0
1954 Dec 28 M 1541228 170345
Acc: 43
2010 Jul 15
Acq Tm: 14:08:22.16

120.0 kV
275.0 mA
5.0 mm/0.0:1
Tilt: 0.0
0.8 s

Se: 3/6
Im: 25/62
Ac: 11:20.0

1954 Dec 28 M 1541228 170345
Acc: 43
2010 Jul 15
Acq Tm: 14:08:22.96

120.0 kV
275.0 mA
5.0 mm/0.0:1
Tilt: 0.0
0.8 s

Se: 3/6
Im: 12/62
Ac: 15:5.0

1954 Dec 28 M 1541228 170345
Acc: 43
2010 Jul 15
Acq Tm: 14:08:20.56

120.0 kV
275.0 mA
5.0 mm/0.0:1

THORAX

2025

Mansour

