ESIM Clinical Case Presentation

The Netherlands

Jeroen Slebe

Claire van Nispen tot Pannerden

Case: 38 yr old Turkish woman

- Presentation A&E: Generally unwell
- Medical history:-

Case: 38 yr old Turkish woman

- Unwell since 2.5 weeks: productive cough; possibly fever and cold shivers.
- Dysuria and hematuria for which GP started co-trimoxazole.
- Jaundice, weightloss, nightsweats, anorexia.

- Last visit to Turkey summer 2010; no known tuberculosis exposure
- Yearly check-up for blooddonorship

Additional questions?

Additional questions?

Married, 2 children, oldest one ‘fluish’; mother and housewife

No smoking

No recent visit to flower parades; no contact with goats or sheep

No known family history

No known allergies

Physical examination

Pale, icteric

- Heart rate 110 bpm; RR 110/67mmHg; T 38°C
- No palpable lymphnodes; no purpura or haematomas
- Cor/ S1S2; no murmur
- Pulm/ rales L>R
- Abdomen/ no signs of hepatosplenomegaly; no loin tenderness
- Skin/ no signs of vasculitis/ septic embolisms

Laboratory

- Hb 2.7 mmol/l (7.5-9.5)
- Ht 0.13 l/l (0.36-0.46)
- Trombo 792*10E9/l (150-370)
- L 35*10E9/l (3.4-10)

- Haptoglob <0.05 g/l (0.28-2)

- Bili 148 ummol/l (<17)
- SGOT 128 U/l (<37)
- SGPT 73 U/l (<31)
- LDH 2880 U/l (<450)

- Creat 64 umol/l (55-90)
- CRP 211 mg/l (<10)

Cough, fever, hemolytic anemia

Cough

- Infectious: upper respiratory infection, pneumonia
- Pulmonary disease: astma, bronchiectasis, malignancy
- Systemic disease: vasculitis
- Gastroesophageal reflux
- Allergic/ toxic

Fever

- Infectious
- Systemic disease
- Malignancy

Hemolytic anemia

- Intrinsic red blood cell defects
- Extrinsic red blood cell defects
- Intravascular destruction of red blood cells

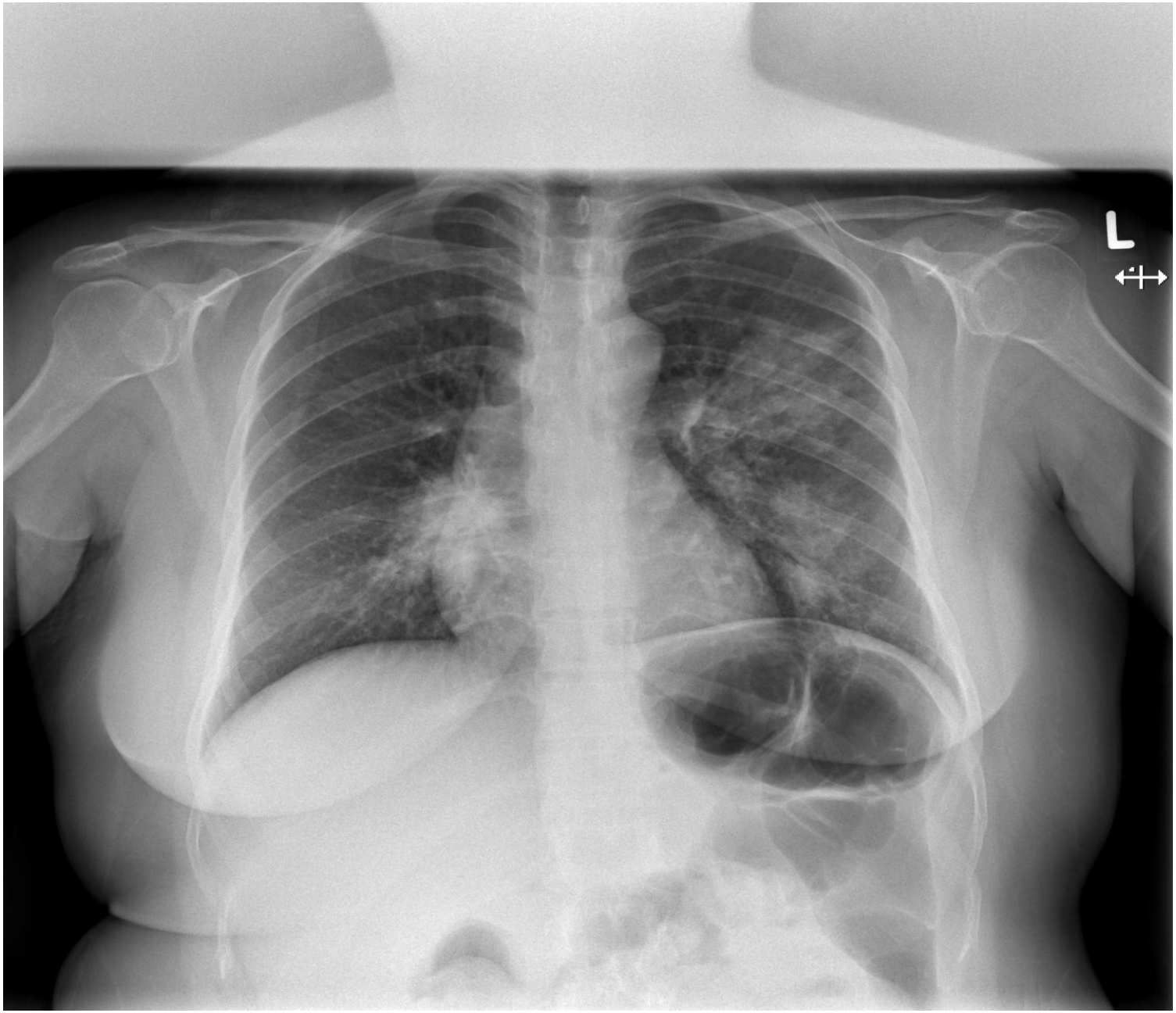
L

More laboratory tests

Bloodtests:

Coombs 3+

Anti IgG 3+

Anti C3b/C3d 3+

Anti IgA 3+

Cold agglutinins 4+

Coombs positive hemolytic anemia

With cold +/- warm agglutinins

- **Idiopathic**
- **Secondary**
  - Lymphoproliferative disease
  - Anti-phospholipid syndrome
  - Drugs
  - Infections

Your diagnosis?

Additional laboratory tests

		21-12-2010	21-12-2010	21-12-2010	22-12-2010	27-12-2010
		K10003868	S10027097	S10027169	E10016048	S10027512
		NESP	SE	SE	KE	SE
Mycoplasma pneumoniae DNA	PCR	*neg*	neg		neg	

Additional laboratory tests

SER	21-12-2010 08:05	SE	Serum/...		LEGS	20100189927402	LEG		LEG: POS 1.218
SER	21-12-2010 08:05	SE	Serum/...		CHLS	20100189927401	KOM		TWEE
SER	21-12-2010 08:05	SE	Serum/...		CHLS	20100189927401	IGG		IGG: NEG < 100
SER	21-12-2010 08:05	SE	Serum/...		CHLS	20100189927401	IGA		IGA: POS 100
SER	21-12-2010 08:05	SE	Serum/...		CHLS	20100189927401	IGM		IGM: POS 1.248

Additional laboratory tests

		21-12-2010	21-12-2010	21-12-2010	22-12-2010	27-12-2010
		K10003868	S10027097	S10027169	E10016048	S10027512
		NESP	SE	SE	KE	SE
anti HIV en p24 Ag	CMIA		neg			
HBsAg	CMIA		neg			
anti HBc	CMIA		neg			
anti hepatitis C virus	CMIA		neg			
IgG anti hepatitis A virus	CMIA		pos			
IgM anti hepatitis A virus	CMIA		neg			
IgG anti CMV	EIA-K		136/P			
IgM anti CMV	EIA		neg			
IgG anti EBV VCA	CLIA-K		pos			
IgM anti EBV VCA	CLIA-K		neg			
IgG anti EBV EA	CLIA-K		grens			
IgG anti EBV NA	CLIA-K		pos			
IgG anti Mycoplasma pneumoniae	EIA-K			49,38/P		56,23/P
IgM anti Mycoplasma pneumoniae	EIA-K			pos		pos
IgG anti B19 virus	EIA		pos			
IgM anti B19 virus	EIA		neg			
cytomegalovirus DNA	PCR		neg			
Epstein-Barr virus DNA	PCR		neg			
B19 virus DNA	PCR		neg			

What’s your diagnosis now?

Pneumonia and extrapulmonary manifestation: hemolysis

QuickTime™ and a
decompressor
are needed to see this picture.

Take home

Atypical pathogens difficult to culture

Syndromic diagnosis essential

Acutely elevated IgM is diagnostic

4-fold increase is indicative

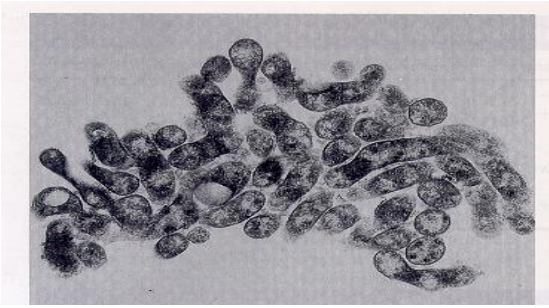

Conclusion

Clinically most likely *Mycoplasma pneumoniae* infection with cold agglutinin induced hemolysis

Good response on treatment with levofloxacine

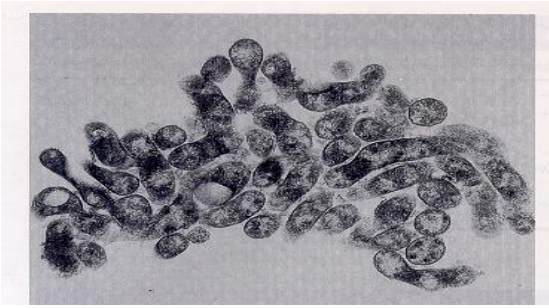

Thank you for your attention!
Views of the Earth, Copyright © 2006 by Christoph Hormann http://earth.imagico.de/

Diagnostics

Bone marrow aspiration: no signs of hematoproliferative disease.

Coombs positive hemolytic

Table 2 Differential diagnosis of noticeable serological findings (*RBC* red blood cells, *HIV* human immunodeficiency virus)

Serological diagnosis	Clinical diagnosis	Direct antiglobulin test (Coombs' test)	Screening for unexpected antibodies	Elution	Remarks
Alloantibodies against blood group antigens	Acute/delayed hemolysis (e.g., transfusion reaction)	Positive (Anti-IgG and/or anti-C3d)	Positive (negative in cases of very low frequent antigens)	Often positive, depends on the transfused antigen count	If the specificity of the antibody is not detectable, use cross-match-negative RBC for transfusion
	Hemolytic anemia after ABO-incompatible bone marrow transplantation	Positive (Anti-IgG and/or anti-C3d)	Weak positive against A and/or B test cells	Positive with A and/or B test cells	In cases of anti-A and/or anti-B transfuse O RBC
Hemolytic disease of the newborn	No, weak mild or strong immunehemolysis due to IgG alloantibodies from the mother (e.g. anti-Rh, -Kell, -Duffy, -Kidd)	Child: positive (Anti-IgG)	Mother and child: positive	Child: positive	Transfuse antigen negative RBC, if necessary
	No or weak immune hemolysis due to ABO incompatibility incompatibility	Child: positive (Anti-IgG)	Negative	Anti-A and/or anti-B	Give O RBC, but in almost all cases no therapy is necessary
Warm autoantibodies	Autoimmune hemolytic anemia of the warm type	Positive with anti-IgG (30–40%) Positive with anti-IgG and anti-C3d (50–60%) Rare: anti-IgA and/or anti-IgM, anti-C3d; very rare: anti-IgA, anti-IgM or anti-C3d alone	Free autoantibodies (50%) Direct AHG reactions are stronger than indirect AHG reactions In almost all cases homogeneous reactions with all test cells	Positive with (e.g., Rh-antibodies -> auto-Anti-e) or without specificity	Problems with blood group typing, cave: alloantibodies
Cold autoantibodies	Weak cold antibodies without hemolysis (e.g. anti-IH)	Negative	Positive at 4°C	Negative	If the titer is high, give warm RBC (37°C)
	Strong hemolysis (Donath-Landsteiner antibodies)	Positive with anti-C3d	Cold agglutinin titer <1:32	Negative	
	No, weak, mild or strong hemolysis due to cold agglutinins	Positive with anti-C3d	Cold agglutinin titer >1:64 Chronic cases >1:2000	Negative	Give warm RBC (37°C)
Activation of complement without antibodies	Immune complex disease	Weak positive with anti-C3d	Negative	Negative	
	Activation of the alternative pathway (viruses, bacteria, dialysis membrane)				
Drug-induced antibodies	No or mild hemolysis due to penicillin or cephalosporin antibodies	Positive with anti-IgG	Positive against penicillin- or cephalosporin-treated RBC	Positive against penicillin- or cephalosporin-treated RBC	Avoid the drug
	Acute intravesse immune hemolysis (drug-induced antibodies)	Positive, normally only with anti-C3d	Positive only in presence of the drug	Often negative	Avoid the drug
	Mixed form (autoantibodies and drug-induced antibodies)	Positive with anti-IgG and anti-C3d Rare: anti-IgA	Positive in case of free antibodies Positive in presence of the drug	Positive	Avoid the drug
Non-specific reactions	Plasma expander, HIV, sepsis, plasmozytom, inflammatory diseases with increasing IgG, liver cirrhosis, hematological disorders	Weak positive with anti-IgG	Often weak positive	Negative	Wash the red cells before laboratory tests

Pruss et al. Clin Exp Med 2003